

# Extracardiac Prothrombotic Effects of COVID-19



Rohan Kankaria, BS<sup>a</sup>, Cristina Sanina, MD<sup>a,b</sup>, Mohamed Gabr, MD<sup>a,b</sup>, Jose Wiley, MD, MPH<sup>a,b</sup>, Anna E. Bortnick, MD, PhD, MSc<sup>a,b,c,\*</sup>

## KEYWORDS

- SARS-CoV-2 • COVID-19 • Thrombosis • Stroke • Deep vein thrombosis • Pulmonary embolism
- Myocardial infarction

## KEY POINTS

- Microvascular thrombosis has macrovascular effects, leading to gross organ dysfunction in COVID-19 infection.
- There is a greater incidence of macrovascular complications such as venous thrombosis, pulmonary embolism (PE), myocardial infarction (MI), and stroke in individuals affected by COVID-19.
- Anticoagulation with unfractionated and low-molecular-weight heparin (LMWH) may be of benefit to reducing thrombosis if started early in the course of COVID-19 illness.
- Prevention of severe COVID-19 illness is important to avoid thrombotic complications, morbidity, and mortality.

## INTRODUCTION

The COVID-19 pandemic has had devastating effects on global health, with greater than 220 million cases and greater than 4 million deaths since January 2020 reported to the World Health Organization.<sup>1,2</sup> Highly transmissible variants risk further spread. In addition to acute respiratory failure, COVID-19 has been linked to arterial and venous thrombosis, especially in those with severe disease.<sup>3</sup> In this review, we summarize data on COVID-19 thrombotic complications (**Central Figure**), delineating the micro- and macrovascular complications that can lead to acute and chronic organ dysfunction and treatment protocols that could lessen the burden of thrombosis.

## MECHANISM OF THROMBOSIS IN COVID-19 ILLNESS

Viral pulmonary diseases elaborate inflammatory cytokines which have prothrombotic effects in

the vasculature of critically ill patients.<sup>4</sup> SARS-CoV-2, the virus causing COVID-19 illness, invades endothelial cells causing local complement activation and inflammation which leads to microvascular thrombosis.<sup>5-7</sup> Amplification of inflammatory and microvascular insult eventually leads to widespread macrovascular thrombotic injury. Patients with COVID-19 experience both venous and arterial thrombosis.

## MICROVASCULAR THROMBOSIS IN COVID-19

Widespread microthrombosis affecting various organ systems is a potential mechanism for long-term sequelae after recovery from COVID-19 which requires investigation. Patients with COVID-19 seem to experience subclinical microvascular thrombosis before developing gross venous or arterial events.<sup>5</sup> One study examining 13 critically ill patients with COVID-19 on mechanical ventilation detected sublingual microthrombi

This article originally appeared in *Cardiology Clinics*, Volume 40, Issue 3, August 2022.

Funding: AEB is supported, in part, by grant K23HL146982 from the National Heart, Lung, and Blood Institute.

<sup>a</sup> Albert Einstein College of Medicine, Montefiore Medical Center, 1300 Morris Park Avenue, Bronx, NY 10461, USA; <sup>b</sup> Department of Medicine, Division of Cardiology, Montefiore Medical Center, 111 E 210th Street, Bronx, NY 10467 USA; <sup>c</sup> Division of Geriatrics, Montefiore Medical Center, 111 E 210th Street, Bronx, NY 10467 USA

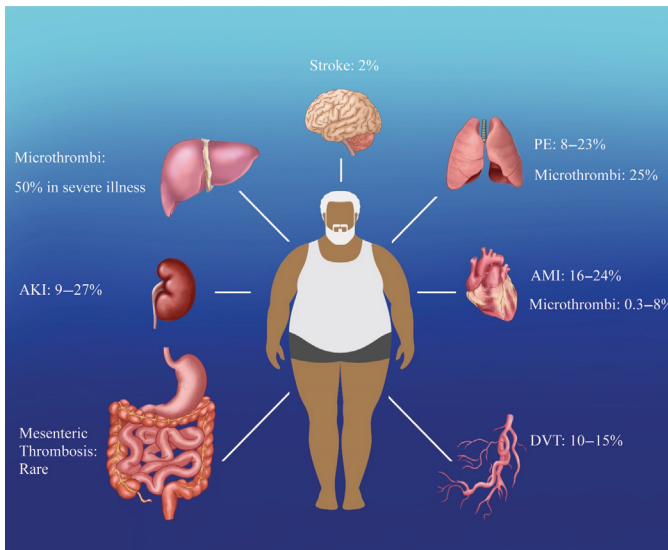
\* Corresponding author. Jack D. Weiler Hospital, 1825 Eastchester Road, Suite 25-46, Bronx, NY 10461.

E-mail address: [abortnic@montefiore.org](mailto:abortnic@montefiore.org)

Heart Failure Clin 19 (2023) 213–220

<https://doi.org/10.1016/j.hfc.2022.08.008>

1551-7136/23/© 2022 Elsevier Inc. All rights reserved.



**Central Figure.** COVID-19 infection predisposes patients to microvascular and macrovascular thrombotic injuries at a higher incidence than the general population. Estimates rounded up. (Compiled from references<sup>10,11,13,20,21,25-27,29-37,43-45,55</sup>. Courtesy of T Harris, Bronx, New York.)

using capillaroscopy, despite none of the patients meeting criteria for diffuse intravascular coagulation.<sup>8</sup> Platelet-rich thrombi have been detected in the pulmonary, renal, cardiac, and hepatic microvasculature, with histopathology indicating increased presence megakaryocytes, a finding suggestive of a cytokine-mediated thrombosis.<sup>9</sup>

### PULMONARY MICROVASCULAR THROMBI

Pulmonary injury in patients with COVID-19 may extend beyond diffuse alveolar disease from acute respiratory distress syndrome. Autopsy reports, though limited, demonstrate extensive complement deposition and diffuse microthrombi predominantly in the septal capillaries.<sup>7,9,10</sup> In a case series of 31 patients with COVID-19, 25% of those with elevated D-dimer levels (>1000 ng/mL) had pulmonary perfusion deficits on computed tomography angiography, but only 2 were noted to have gross pulmonary embolism (PE).<sup>10</sup> Patients with perfusion deficits had higher intensive care unit (ICU) admission rates (37.5% vs 4.3%,  $P = .043$ ), higher body mass indices (BMI) (28.85 vs 25.94  $P = .040$ ), and higher likelihood of severe disease (50% vs 4.3%,  $P = .01$ ) when compared with patients without perfusion deficits.<sup>10</sup>

### RENAL MICROVASCULAR THROMBI

The incidence of acute kidney injury (AKI) in patients with COVID-19 is high, from 9% to 27% in retrospective studies, and similar to patients who have other pneumonias.<sup>11-13</sup> Many factors contribute to AKI, but findings from biopsy studies suggest that it is compounded by microvascular

thrombosis. Autopsies from 6 patients showed widespread acute tubular necrosis and glomerular capillary damage from complement activity.<sup>11</sup> Viral inclusions were found in kidney cells supporting direct infection as a mechanism of localized cell death and inflammatory response. Renal perfusion deficits have been observed on imaging, as well.<sup>10</sup> Renal biopsy studies, though limited, demonstrate thrombotic microangiopathy, complement deposition in the mesangial space, fibrin thrombi in the glomeruli, and cortical necrosis in patients with severe AKI.<sup>14,15</sup> Hypercoagulability, defined as a low ADMATS13/VWF antigen ratio, was strongly associated with worsened AKI and severe illness, further supporting renal microthrombosis as a contributory factor to the high incidence of AKI in patients with COVID-19.<sup>16</sup>

### DERMATOLOGIC AND OPHTHALMOLOGIC MICROVASCULAR THROMBI

There have been multiple case reports of dermatologic and ophthalmologic microvascular thrombosis.<sup>7,17-19</sup> Patients with pulmonary hemorrhage on autopsy were also found to have complement deposition in the dermal microvasculature.<sup>7</sup> Inflammation of the dermal microvasculature (chilblains) has been reported.<sup>17</sup> Interestingly, complement deposition in skin has also been documented from patients with COVID-19 who did not exhibit pulmonary deficits or obvious skin findings.<sup>7</sup>

There is a singular report of retinal vasculitis in a child, as well as an autopsy series demonstrating ocular endothelial cell damage and fibrin microvascular thrombi in severe COVID-19 illness.<sup>17,18</sup> However, a larger retrospective cohort study

found no significant difference when comparing patients with COVID-19 and controls for vascular perfusion in the superficial or deep vascular plexus of the eye, suggesting that it is possible that microthrombi may dissipate with the resolution of disease or that the eye may be spared in many instances.<sup>19</sup>

### MYOCARDIAL MICROVASCULAR THROMBI

COVID-19 illness has been associated with myocardial infarction (MI), myocarditis, and cardiomyopathy (reviewed in Kite and colleagues' article, "The Direct and Indirect Effects of COVID-19 on Acute Coronary Syndromes," in this issue). The incidence of MI in patients with COVID-19 has been estimated to range from 0.33% to 8%.<sup>20,21</sup> COVID-19-associated ST-elevation myocardial infarction (STEMI) has been well described and is associated with higher mortality compared with STEMI in patients without COVID-19 infection.<sup>22</sup> However, there are few studies analyzing the extent of microvascular injury in the myocardium. Autopsies of 7 patients showed fibrin microthrombi and megakaryocytes within the myocardial microvasculature in all patients and 2 had macrovascular myocardial venous thrombosis.<sup>9</sup> In a larger, multi-center autopsy study of 21 patients, 4 had fibrin and platelet microthrombi (PMT) in the myocardial microvasculature and 3 had fibrin and PMT in the endocardial microvasculature.<sup>23</sup> These results suggest that patients with severe COVID-19 infection are predisposed to developing myocardial microthrombi. Further studies are necessary to understand the long-term clinical effects on cardiac function.

### HEPATIC MICROVASCULAR THROMBI

COVID-19 illness is associated with acute liver injury. Proposed mechanisms of injury are systemic inflammation, hepatic ischemia, drug toxicity, and hepatic microthrombi, which have been seen on autopsy.<sup>9,24</sup> A series of postmortem liver biopsies in patients with COVID-19, without preexisting liver disease or clinical signs of hepatic failure, found that greater than 50% had sinusoidal microthrombi and those individuals had 10-fold higher liver enzyme levels than those who did not have microthrombi.<sup>25</sup> Liver involvement in severe COVID-19 infection was confirmed in a second autopsy series demonstrating hepatic steatosis and elevated megakaryocytes in hepatic sinusoids, which were associated with systemically elevated D-dimer and liver enzyme levels in those individuals.<sup>26</sup>

Importantly, 2 types of microthrombi have been described in hepatic sinusoids: sinusoidal erythrocyte aggregation (SEA) and PMT. PMT thrombosis was associated with significant steatosis as compared with patients with COVID-19 without sinusoidal microthrombosis (79% vs 35%,  $P = .02$ ).<sup>25</sup> Both PMT and SEA thrombosis were associated with significant neutrophil accumulation in the hepatic sinusoids, illustrating the inflammatory component of microthrombotic injury. Compared with SEA, patients with PMT thrombosis were found to have increased incidence of liver injury.<sup>25</sup>

Conversely, a third large autopsy series found minimal microthrombi, with 50% having mild hepatitis and 75% with macrovesicular steatosis. Hepatic vascular findings were limited to scarce nondiffuse vascular abnormalities with 6 patients showing signs of veno-occlusive disease and 5 patients showing signs of arteriolar muscular hyperplasia.<sup>27</sup> Of note, in all 3 autopsy studies, steatosis was not associated with obesity or diabetes, suggesting that hepatic steatosis in these decedents of COVID-19 was not secondary to nonalcoholic fatty liver disease, but more likely a consequence of inflammation.<sup>25</sup>

### MACROVASCULAR THROMBOSIS IN COVID-19

The mechanism of macrovascular thrombosis seems to be an extension of the proposed mechanisms delineating microvascular thrombosis. Pro-inflammatory mediated cytokine release and direct endothelial damage activate the coagulation cascade leading to widespread macrovascular thrombosis, including PE, deep vein thrombosis (DVT), stroke, and MI.<sup>28</sup>

### PULMONARY EMBOLISM

COVID-19 has been associated with an increased incidence of PE ranging from 8.3% to 23%, depending on the severity of illness, based on retrospective studies.<sup>29-31</sup> In comparison, the incidence of any venous thrombosis in the general population is 0.1%.<sup>32</sup> There is conflicting evidence that obesity predisposes to developing PE in the context of COVID-19 and it may depend on the severity of illness. Male sex and concomitant cardiovascular disease (CVD) are potentially predisposing factors, as well.<sup>31</sup> Multiple studies indicate that patients with PE have higher D-dimer levels when compared with patients with COVID-19 without PE, suggesting that D-dimer levels can be used for diagnostics, prognostic purposes, and risk stratification.<sup>29-31</sup>

In a study of moderate COVID-19, there was a lower incidence of PE (8.3%) and neither obesity nor diabetes was predisposing factors.<sup>30</sup> Patients who were treated with anticoagulation, either prophylactic or therapeutic dose, low-molecular-weight heparin (LMWH) or subcutaneous unfractionated heparin (UFH) before or during hospitalization, had a significantly lower odds for developing PE.<sup>30</sup> Importantly, PE was more likely to develop in patients with delayed hospitalization.<sup>30</sup> Interestingly, in a study of all-comers on statins precluding mild, moderate or severe COVID-19 illness, treatment resulted in a significantly lower odds ratio (OR) of PE; OR: 0.4 [95% confidence interval (CI): 0.23–0.75].<sup>29</sup> Thus, anticoagulation, statins, and modulating the intensity of the inflammatory response to COVID-19 may be helpful in avoiding PE in hospitalized individuals.

### VENOUS THROMBOEMBOLISM AND ARTERIAL THROMBOEMBOLIC COMPLICATIONS

Multi-center inpatient studies show a 10% to 14.7% incidence of venous thromboembolism in COVID-19 illness compared with 0.1% of the general population, but up to as high as 45.4% in ICU-level patients.<sup>32–35</sup> Many develop asymptomatic DVT. Some centers only screened symptomatic patients; thus, the incidence is likely underreported in those studies. Like PE, patients with COVID-19 with DVT had higher D-dimer levels.<sup>34–36</sup> There were no differences in baseline sex, age, or BMI of patients with COVID-19 who developed DVT as compared with those who did not, in limited studies.<sup>34–36</sup> Additionally, DVT was linked to worse multi-system organ function and breakthrough from prophylactic anticoagulation.

A large, single-center, retrospective study of 362 patients found an incidence of total venous and arterial thromboembolic events of 7.7%, but this number may be underestimated as there was no surveillance of asymptomatic patients.<sup>36</sup> Most of those diagnosed with DVT also had concomitant PE; nonsurvivors had higher D-dimer levels.<sup>36</sup>

A prospective study of 156 COVID-19 positive inpatients evaluated the incidence of asymptomatic DVT. Patients received standard DVT prophylaxis of enoxaparin 40 mg per day or bemiparin 3500 IU per day. Of the 156 surveilled, 23 patients (14.7%) developed DVT with the majority (22/23) developing distal DVT. Patients who developed DVT had higher average D-dimer levels than those without (4527 vs 2050 ng/mL,  $P < .001$ ).<sup>35</sup> There was no significant difference in obesity, sex, or

age in patients who developed DVT versus those who did not.<sup>35</sup>

The incidence of DVT seems higher in critically ill patients with COVID-19.<sup>34</sup> In a retrospective, single-center analysis of 88 ICU patients receiving thromboprophylaxis with LMWH, 40 developed DVT (45.4%).<sup>34</sup> In this study, DVT was not associated with BMI, age, sex, and platelet counts, but was associated with elevated sequential organ failure assessment (SOFA) scores (6 vs 4,  $P < .001$ ), elevated D-dimer levels (6.4 vs 3.1 mg/L,  $P < .02$ ), hypoalbuminemia (28.81 vs 32.39 g/L,  $P < .001$ ) and longer duration of illness (34 vs 20 days,  $P = .007$ ). Anatomically, most DVTs were distal and bilateral.<sup>34</sup> Thus, prophylactic LMWH may be insufficient for the prevention of DVT in the ICU population.

### STROKE

The incidence of stroke in COVID-19 infection is approximately 1.7%.<sup>37</sup> By comparison, the risk of stroke in the general population is 0.2%.<sup>38</sup> Studies point to severe COVID-19 infection or underlying cardiovascular risk factors as highly contributory to stroke.<sup>39,40</sup> In comparison to incident DVT and PE, there seems to be a stronger association of underlying CVD risk factors with COVID-19-associated stroke.

Retrospective case-control studies have documented increased stroke in hospitalized COVID-19 patients, and conversely, more frequent COVID-19 infection in those hospitalized with stroke during the time frame of the pandemic. COVID-19 was more often associated with stroke in Black individuals in a larger, multicenter analysis.<sup>39</sup> Black individuals with COVID-19 comprised a greater proportion of stroke cases compared with noninfected Black controls (44.7% vs 19.6%,  $P < .0001$ ).<sup>39</sup> Conversely, White individuals with COVID-19 accounted for a smaller proportion of stroke cases compared with White individuals without COVID-19 (35.9% vs 56.3,  $P < .0001$ ).<sup>39</sup> Patients with hypertension, type 2 diabetes mellitus (T2DM), atrial fibrillation, and congestive heart failure at baseline were more likely to develop stroke. Hospitalized patients with COVID-19-associated stroke had higher mortality rates (19.4% vs 6.2%,  $P < .0001$ ), longer hospital stay, and more frequently had concomitant MI (10.7% vs 4.6%,  $P = .003$ ).<sup>39</sup>

From March to April 2020, COVID-19 was more frequently diagnosed in those with stroke, after adjusting for age, sex, vascular risk factors, and underlying comorbidities.<sup>41</sup> Patients presenting with stroke were infected with COVID-19 46.3% of the time as compared with 18.3% of the time

for nonstroke patients ( $P = .001$ ).<sup>41</sup> Similar data from a single-center retrospective study support the observation that severe COVID-19, hypertension and T2DM are associated with increased incidence of stroke, but in this study, age was a significant factor as well, with all strokes occurring in patients greater than 60 years.<sup>40</sup> Patients with COVID-19 infected stroke have poorer outcomes and prolonged neurologic deficits, with worse neurologic disabilities at discharge and a higher incidence of delirium than stroke patients without COVID-19.<sup>42</sup>

## INTESTINAL VASCULAR COMPLICATIONS

Acute mesenteric ischemia and mesenteric venous thrombosis are rare complications of COVID-19, thus, data are limited.<sup>43–45</sup> Clinicians should be vigilant for intestinal thrombotic injury in the correct context. In a case report, one patient presented with mesenteric venous thrombosis after presenting 20 days after the onset of COVID-19 with severe abdominal pain, suggesting prolonged hypercoagulability in some individuals.<sup>45</sup>

## PREVENTION AND TREATMENT OF THROMBOSIS IN COVID-19 INFECTION

There is varying evidence on indications, dose, and efficacy of medical therapy for thrombotic complications of COVID-19. Studies suggest the greatest effect in preventing thrombotic injury is with heparins rather than direct oral anticoagulants (DOAC).<sup>46–49</sup> It is important to note that many studies are nonrandomized and focus on macrovascular rather than microvascular thrombosis.

Heparin has been studied in several randomized controlled clinical trials in noncritically and critically ill patients.<sup>46,47</sup> Patients were randomized to either therapeutic doses of UFH or LMWH based on local dosing protocols or standard thromboprophylaxis. In noncritically ill patients, therapeutic heparin increased organ support-free days, defined as the total number of days without respiratory or cardiovascular support, OR: 1.27 (95% CI: 1.03–1.58). Patients on therapeutic heparin were less likely to die (OR: 0.72 95% CI: 0.53–0.98). There was a nonstatistically significant increase in bleeding (OR: 1.8, 95% CI: 0.9–3.74).<sup>46</sup> By comparison, patients with critically ill COVID-19 on therapeutic anticoagulation did not have a significant improvement in organ support-free days or mortality. Thrombosis and risk of major bleeding were similar between treatment assignments.<sup>47</sup> Thus, the optimal window for therapeutic anticoagulation may be early in the course of illness. Accordingly, in a retrospective study looking at the incidence of PE in patients with COVID-19,

non-ICU level COVID-19 individuals on prophylactic anticoagulation were found to have a lower incidence of PE later in the course of their illness.<sup>30</sup>

DOACs have also been studied in patients with COVID-19.<sup>48</sup> In a large randomized control trial, patients were randomized to therapeutic or prophylactic doses.<sup>48</sup> Most received rivaroxaban; however, unstable patients received enoxaparin and were later switched to rivaroxaban once stable, while a minority received UFH. There was no reduction in the duration of hospitalization or supplemental oxygen, DVT, PE, MI, stroke, or death with therapeutic anticoagulation and there were no differences when stratifying for stability. Clinically significant bleeding events were more common in patients receiving therapeutic anticoagulation (8% vs 2%,  $P = .001$ ).<sup>48</sup>

Another large multicenter retrospective study demonstrated the benefit of anticoagulation with either warfarin or DOACs (dabigatran, rivaroxaban, or apixaban) predating COVID-19, supporting the hypothesis that early anticoagulation is most beneficial in preventing thrombosis during infection.<sup>49</sup> Patients in this study were older, more likely to have hypertension, T2DM, dyslipidemia, and cardiovascular risk factors; a high-risk group for developing prothrombotic complications of COVID-19. Patients who were on therapeutic oral anticoagulation at baseline had less ICU admission, RR 0.45 (95% CI: 0.32–0.62), and lower combined ICU admission and death, RR 0.72 (95% CI: 0.57–0.9), after adjustment. Anticoagulation after hospitalization did not significantly alter ICU admission or death in this observational cohort.<sup>49</sup> However, this finding is contradicted by a retrospective study of hospitalized patients receiving apixaban, enoxaparin, or heparin.<sup>50</sup> Patients on apixaban at prophylactic or therapeutic doses showed lower adjusted odds for death OR: 0.46, (95% CI: 0.30–0.71) and OR: 0.57, (95% CI: 0.38–0.85), respectively, as compared with patients who were not treated. In this study, neither prophylactic nor therapeutic doses of UFH were of benefit. Stratifying by D-dimer levels indicated that patients with low levels of less than 1  $\mu\text{g/mL}$  did not benefit from anticoagulation therapy. However, patients with D-dimer  $\geq 1 \mu\text{g/mL}$  had lower mortality on either enoxaparin at prophylactic doses or apixaban at prophylactic or therapeutic doses.<sup>50</sup>

A recent, multicenter, randomized controlled trial studied the use of antiplatelet and anticoagulation therapy in outpatients symptomatic of COVID-19. Patients were randomized into one of the following arms: aspirin 81 mg once daily, apixaban 2.5 mg twice daily (prophylactic dosage), apixaban 5 mg twice daily (therapeutic dosage), or placebo. Patients were excluded if they were

previously hospitalized with COVID-19, had other indications for anticoagulation, or had recent major bleeding events.<sup>51</sup> When compared with placebo, treatment with aspirin and apixaban showed no reduction in thrombotic events (DVT, PE, arterial thromboembolism, MI, and stroke). There was an increased risk of minor bleeding in patients receiving therapeutic apixaban with an increased risk difference of 6.9 (95% CI: 1.4–12.9).<sup>51</sup>

Anti-platelet agents, including aspirin, P2Y<sub>12</sub> inhibitors, and dual antiplatelet therapy (DAPT) do not seem to be beneficial in preventing death or progression of COVID-19 in small retrospective studies.<sup>52,53</sup> A larger, retrospective, multicenter study showed that patients who received aspirin before hospitalization had lower mortality rates, ICU admission, and need for mechanical ventilation.<sup>54</sup> These patients were also more likely to have underlying medical comorbidities such as hypertension, coronary artery disease, and T2DM.

Current therapeutic guidelines to prevent thrombotic complications of COVID-19 are limited by the lack of sufficient randomized control trials of various anticoagulation and antiplatelet regimens. Limited data from randomized trials suggest that early heparin anticoagulation, before progression to severe COVID-19, may decrease thrombotic complications and death.<sup>30,46,47</sup>

## SUMMARY

COVID-19 is associated with multi-organ arterial and venous thrombosis, particularly in individuals who are older, obese, and living with T2DM. Black patients appear more predisposed to COVID-19-associated stroke than White patients. Patients with COVID-19 can develop asymptomatic DVT. Prophylactic LMWH may be insufficient for the prevention of DVT in the ICU population. Anticoagulation with unfractionated and LMWH may be of benefit to reducing thrombosis if started early in the course of COVID-19 illness.

Randomized control trials are necessary to delineate the most effective regimens to prevent and treat thrombotic events from COVID-19 infection. Additional research on long-term consequences of microvascular thrombotic injury and organ dysfunction is required to understand the implications for survivors. Preventing severe infection remains of strategic importance in reducing morbidity and mortality from COVID-19-associated thrombosis.

## DISCLOSURE

The authors have no conflicts relating to the published work.

## CLINICAL CARE POINTS

- Worsening clinical courses such as hypoxia, acute kidney injury (AKI), rising liver enzymes, rising D-dimer levels, or persistent fevers may point to COVID-19 associated thrombosis.
- Prophylactic anticoagulation in mild infection or therapeutic anticoagulation with low molecular weight heparin (LMWH) in moderate or symptomatic disease may prevent major thrombotic events.
- Antifactor Xa activity monitoring may be useful for guiding the titration of therapeutic LMWH in COVID-19 infection.
- Early intervention to slow disease progression may help decrease the risk of associated thrombosis and should be investigated in further research.
- Anticoagulation with unfractionated or LMWH may be insufficient to prevent thrombosis in severe COVID-19 infection. Whether direct thrombin inhibitors are more effective in this context requires investigation, but could be considered in the critically ill.

## ACKNOWLEDGMENTS

The authors thank Tatyana A. Harris, Albert Einstein College of Medicine Creative Services, for designing the Central Figure.

## REFERENCES

1. Koyama T, Weeraratne D, Snowdon JL, et al. Emergence of Drift variants that may Affect COVID-19 Vaccine Development and Antibody treatment. *Pathogens* 2020;9(5).
2. Organization WH. WHO coronavirus (COVID-19) Dashboard. 2021. Available at: <https://covid19.who.int>. Accessed October 1, 2021.
3. Helms J, Tacquard C, Severac F, et al. High risk of thrombosis in patients with severe SARS-CoV-2 infection: a multicenter prospective cohort study. *Intensive Care Med* 2020;46(6):1089–98.
4. Goeijenbier M, van Wissen M, van de Weg C, et al. Review: Viral infections and mechanisms of thrombosis and bleeding. *J Med Virol* 2012;84(10):1680–96.
5. Page EM, Ariens RAS. Mechanisms of thrombosis and cardiovascular complications in COVID-19. *Thromb Res* 2021;200:1–8.
6. Varga Z, Flammer AJ, Steiger P, et al. Endothelial cell infection and endotheliitis in COVID-19. *Lancet* 2020;395(10234):1417–8.

7. Magro C, Mulvey JJ, Berlin D, et al. Complement associated microvascular injury and thrombosis in the pathogenesis of severe COVID-19 infection: a report of five cases. *Transl Res* 2020;220:1–13.
8. do Espirito Santo DA, Lemos ACB, Miranda CH. In vivo demonstration of microvascular thrombosis in severe COVID-19. *J Thromb Thrombolysis* 2020; 50(4):790–4.
9. Rapkiewicz AV, Mai X, Carsons SE, et al. Megakaryocytes and platelet-fibrin thrombi characterize multi-organ thrombosis at autopsy in COVID-19: a case series. *EClinicalMedicine* 2020;24:100434.
10. Idilman IS, Telli Dizman G, Ardali Duzgun S, et al. Lung and kidney perfusion deficits diagnosed by dual-energy computed tomography in patients with COVID-19-related systemic microangiopathy. *Eur Radiol* 2021;31(2):1090–9.
11. Diao B, Wang C, Wang R, et al. Human kidney is a target for novel severe acute respiratory syndrome coronavirus 2 infection. *Nat Commun* 2021;12(1): 2506.
12. Sise ME, Baggett MV, JO Shepard, et al. Case 17-2020: a 68-year-Old man with Covid-19 and acute kidney injury. *N Engl J Med* 2020;382(22):2147–56.
13. Chen YT, Shao SC, Hsu CK, et al. Incidence of acute kidney injury in COVID-19 infection: a systematic review and meta-analysis. *Crit Care* 2020;24(1):346.
14. Boudhabhay I, Rabant M, Roumenina LT, et al. Case report: Adult post-COVID-19 Multisystem inflammatory syndrome and thrombotic microangiopathy. *Front Immunol* 2021;12:680567.
15. Jhaveri KD, Meir LR, Flores Chang BS, et al. Thrombotic microangiopathy in a patient with COVID-19. *Kidney Int* 2020;98(2):509–12.
16. Henry BM, Benoit SW, de Oliveira MHS, et al. ADAMTS13 activity to von Willebrand factor antigen ratio predicts acute kidney injury in patients with COVID-19: evidence of SARS-CoV-2 induced secondary thrombotic microangiopathy. *Int J Lab Hematol* 2021;43(Suppl 1):129–36.
17. Quintana-Castanedo L, Feito-Rodriguez M, Fernandez-Alcalde C, et al. Concurrent chilblains and retinal vasculitis in a child with COVID-19. *J Eur Acad Dermatol Venereol* 2020;34(12):e764–6.
18. Reinhold A, Tzankov A, Matter MS, et al. Ocular pathology and Occasionally detectable Intraocular severe acute respiratory syndrome coronavirus-2 RNA in five fatal coronavirus disease-19 cases. *Ophthalmic Res* 2021;64(5):785–92.
19. Savastano MC, Gambini G, Cozzupoli GM, et al. Retinal capillary involvement in early post-COVID-19 patients: a healthy controlled study. *Graefes Arch Clin Exp Ophthalmol* 2021;259(8):2157–65.
20. Modin D, Claggett B, Sindet-Pedersen C, et al. Acute COVID-19 and the incidence of ischemic stroke and acute myocardial infarction. *Circulation* 2020;142(21):2080–2.
21. Li B, Yang J, Zhao F, et al. Prevalence and impact of cardiovascular metabolic diseases on COVID-19 in China. *Clin Res Cardiol* 2020;109(5):531–8.
22. Saad M, Kennedy KF, Imran H, et al. Association between COVID-19 Diagnosis and in-hospital mortality in patients hospitalized with ST-Segment elevation myocardial infarction. *JAMA* 2021;326(19):1940–52.
23. Basso C, Leone O, Rizzo S, et al. Pathological features of COVID-19-associated myocardial injury: a multicentre cardiovascular pathology study. *Eur Heart J* 2020;41(39):3827–35.
24. Hundt MA, Deng Y, Ciarleglio MM, et al. Abnormal liver Tests in COVID-19: a retrospective observational cohort study of 1,827 patients in a major U.S. Hospital Network. *Hepatology* 2020;72(4): 1169–76.
25. Kondo R, Kawaguchi N, McConnell MJ, et al. Pathological characteristics of liver sinusoidal thrombosis in COVID-19 patients: a series of 43 cases. *Hepatol Res* 2021;51(9):1000–6.
26. Zhao CL, Rapkiewicz A, Maghsoodi-Deerwester M, et al. Pathological findings in the postmortem liver of patients with coronavirus disease 2019 (COVID-19). *Hum Pathol* 2021;109:59–68.
27. Lagana SM, Kudose S, Iuga AC, et al. Hepatic pathology in patients dying of COVID-19: a series of 40 cases including clinical, histologic, and virologic data. *Mod Pathol* 2020;33(11):2147–55.
28. Kamel MH, Yin W, Zavaro C, et al. Hyperthrombotic Milieu in COVID-19 patients. *Cells* 2020;9(11).
29. Poyiadji N, Cormier P, Patel PY, et al. Acute pulmonary embolism and COVID-19. *Radiology* 2020; 297(3):E335–8.
30. Fauvel C, Weizman O, Trimaille A, et al. Pulmonary embolism in COVID-19 patients: a French multi-centre cohort study. *Eur Heart J* 2020;41(32): 3058–68.
31. Faggiano P, Bonelli A, Paris S, et al. Acute pulmonary embolism in COVID-19 disease: Preliminary report on seven patients. *Int J Cardiol* 2020;313: 129–31.
32. White RH. The epidemiology of venous thromboembolism. *Circulation* 2003;107(23 Suppl 1):I4–8.
33. Boonyawat K, Chantrathamchart P, Numthavaj P, et al. Incidence of thromboembolism in patients with COVID-19: a systematic review and meta-analysis. *Thromb J* 2020;18(1):34.
34. Chen S, Zhang D, Zheng T, et al. DVT incidence and risk factors in critically ill patients with COVID-19. *J Thromb Thrombolysis* 2021;51(1):33–9.
35. Demelo-Rodriguez P, Cervilla-Munoz E, Ordieres-Ortega L, et al. Incidence of asymptomatic deep vein thrombosis in patients with COVID-19 pneumonia and elevated D-dimer levels. *Thromb Res* 2020;192:23–6.
36. Lodigiani C, Iapichino G, Carenzo L, et al. Venous and arterial thromboembolic complications in

- COVID-19 patients admitted to an academic hospital in Milan, Italy. *Thromb Res* 2020;191:9–14.
37. Siow I, Lee KS, Zhang JJY, et al. Stroke as a neurological complication of COVID-19: a systematic review and meta-analysis of incidence, outcomes and Predictors. *J Stroke Cerebrovasc Dis* 2021; 30(3):105549.
  38. Rosamond WD, Folsom AR, Chambless LE, et al. Stroke incidence and survival among middle-aged adults: 9-year follow-up of the Atherosclerosis Risk in Communities (ARIC) cohort. *Stroke* 1999;30(4): 736–43.
  39. Qureshi AI, Baskett WI, Huang W, et al. Acute ischemic stroke and COVID-19: an analysis of 27 676 patients. *Stroke* 2021;52(3):905–12.
  40. Li Y, Li M, Wang M, et al. Acute cerebrovascular disease following COVID-19: a single center, retrospective, observational study. *Stroke Vasc Neurol* 2020; 5(3):279–84.
  41. Belani P, Schefflein J, Kihira S, et al. COVID-19 is an Independent risk factor for acute ischemic stroke. *AJNR Am J Neuroradiol* 2020;41(8):1361–4.
  42. Benussi A, Pilotto A, Premi E, et al. Clinical characteristics and outcomes of inpatients with neurologic disease and COVID-19 in Brescia, Lombardy, Italy. *Neurology* 2020;95(7):e910–20.
  43. Fan BE, Chang CCR, Teo CHY, et al. COVID-19 Coagulopathy with Superior mesenteric vein thrombosis complicated by an Ischaemic Bowel. *Hamostaseologie* 2020;40(5):592–3.
  44. Singh B, Mechineni A, Kaur P, et al. Acute intestinal ischemia in a patient with COVID-19 infection. *Korean J Gastroenterol* 2020;76(3):164–6.
  45. Aleman W, Cevallos LC. Subacute mesenteric venous thrombosis secondary to COVID-19: a late thrombotic complication in a nonsevere patient. *Radiol Case Rep* 2021;16(4):899–902.
  46. Investigators A, Investigators AC-a, Investigators R-C, et al. Therapeutic anticoagulation with heparin in Noncritically ill patients with Covid-19. *N Engl J Med* 2021;385(9):790–802.
  47. Investigators R-C, Investigators AC-a, Investigators A, et al. Therapeutic anticoagulation with heparin in critically ill patients with Covid-19. *N Engl J Med* 2021;385(9):777–89.
  48. Lopes RD, de Barros ESPGM, Furtado RHM, et al. Therapeutic versus prophylactic anticoagulation for patients admitted to hospital with COVID-19 and elevated D-dimer concentration (ACTION): an open-label, multicentre, randomised, controlled trial. *Lancet* 2021;397(10291):2253–63.
  49. Chocron R, Galand V, Cellier J, et al. Anticoagulation before hospitalization is a potential Protective factor for COVID-19: Insight from a French multicenter cohort study. *J Am Heart Assoc* 2021;10(8): e018624.
  50. Billett HH, Reyes-Gil M, Szymanski J, et al. Anticoagulation in COVID-19: effect of enoxaparin, heparin, and apixaban on mortality. *Thromb Haemost* 2020; 120(12):1691–9.
  51. Connors JM, Brooks MM, Scirba FC, et al. Effect of antithrombotic therapy on clinical outcomes in outpatients with clinically stable symptomatic COVID-19: the ACTIV-4B randomized clinical trial. *JAMA* 2021;326(19):1940–52.
  52. Russo V, Di Maio M, Attena E, et al. Clinical impact of pre-admission antithrombotic therapy in hospitalized patients with COVID-19: a multicenter observational study. *Pharmacol Res* 2020;159:104965.
  53. Banik JM V, Köhler C, Schmidtman M. Antiplatelet therapy in patients with Covid-19: a retrospective observational study. *Thromb Update* 2021;2.
  54. Chow JH, Khanna AK, Kethireddy S, et al. Aspirin Use is associated with decreased mechanical ventilation, intensive care Unit admission, and in-hospital mortality in hospitalized patients with coronavirus disease 2019. *Anesth Analg* 2021;132(4):930–41.
  55. Prasitlunkum N, Chokesuwattanaskul R, Thongprayoon C, et al. Incidence of myocardial injury in COVID-19-infected patients: a systematic review and meta-analysis. *Diseases (Basel, Switzerland)* 2020;8(4).